

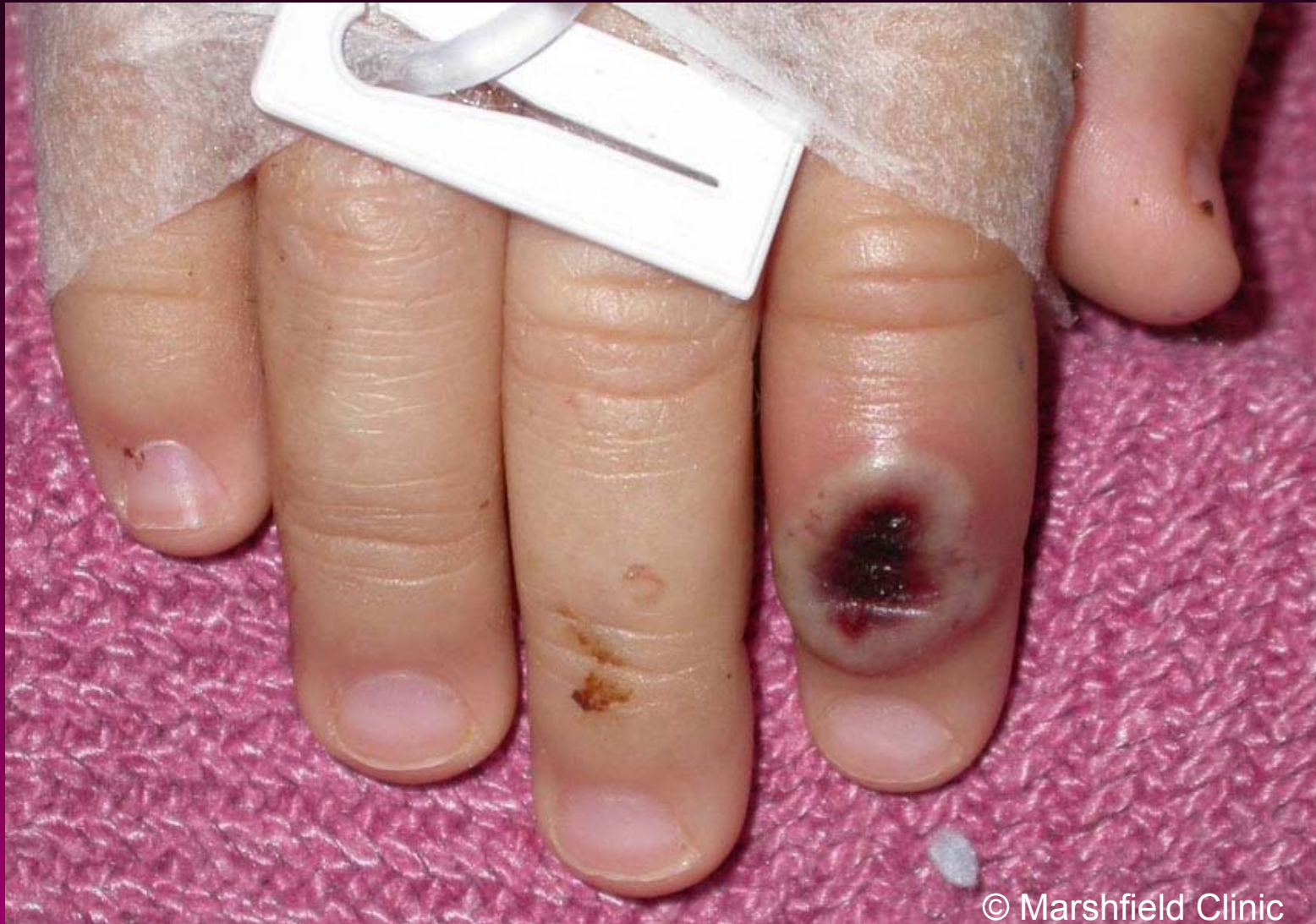# Index case and family infection of Monkey Pox from Prairie Dogs diagnosed in Marshfield, WI ( Clinical Photos )

---

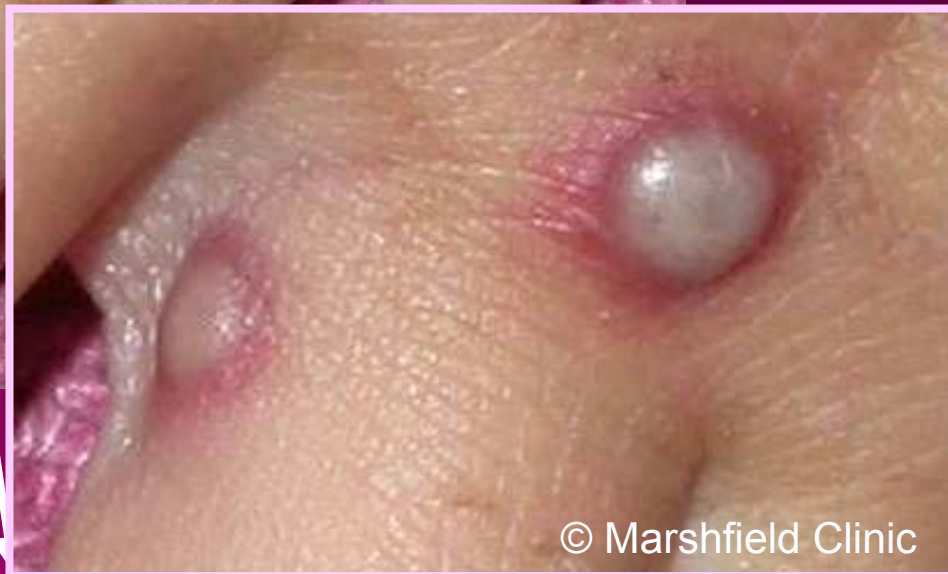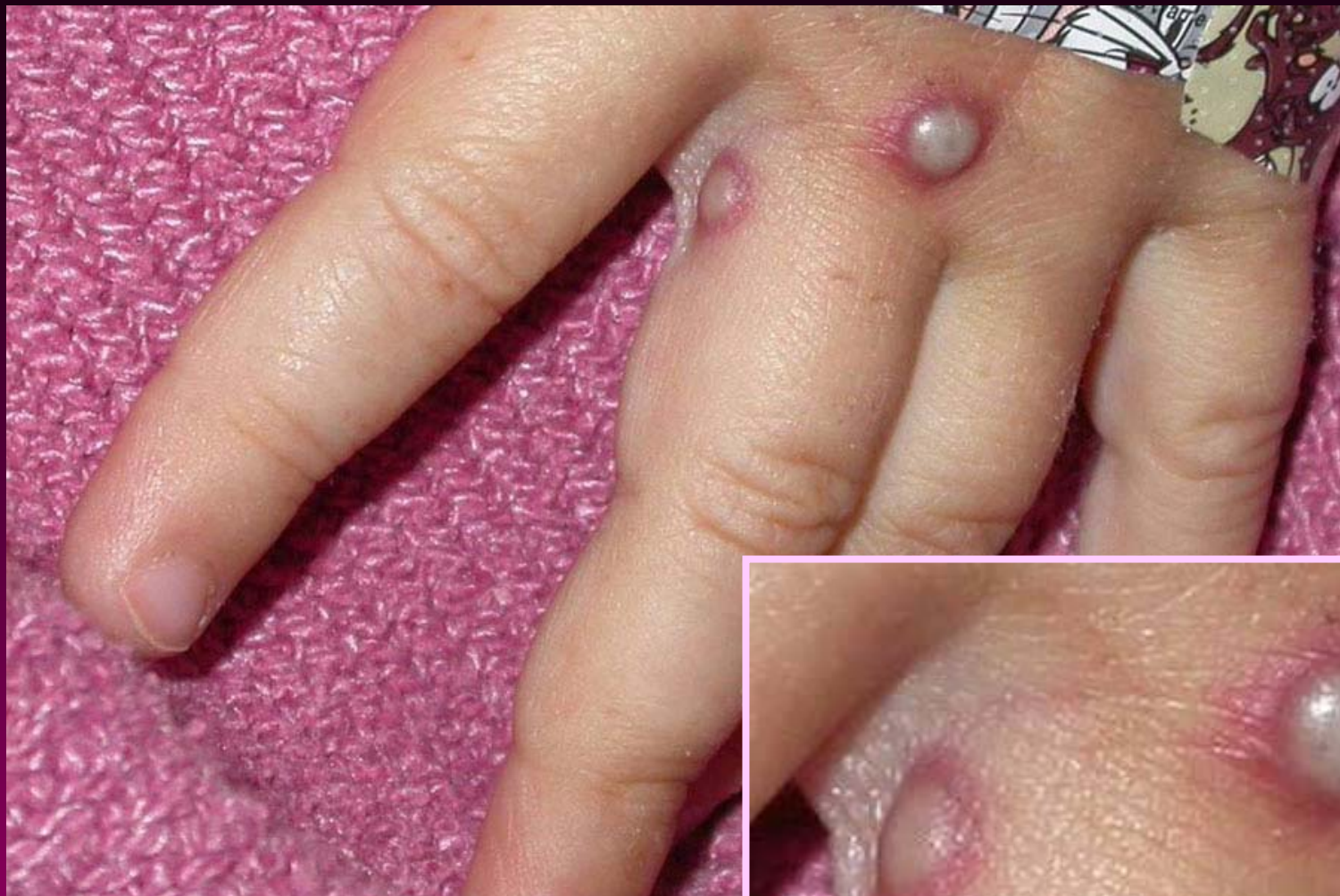Kurt Reed MD  
John Melski MD  
Erik Stratman MD

Marshfield Clinic May-June 2003

Child, Marshfield Index Case: Primary inoculation site right index finger, 5/27/03. 14 days after prairie dog bites, 11 days after febrile illness, hospital day 5.

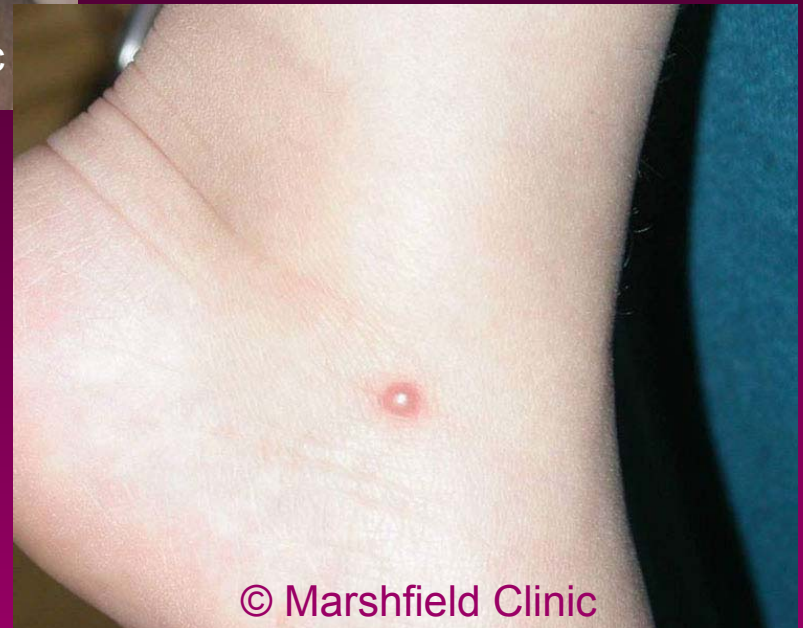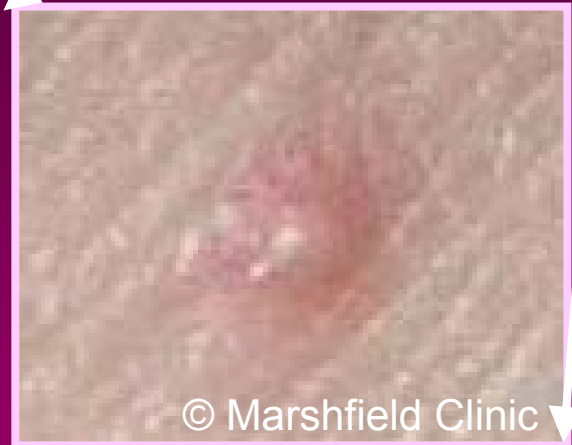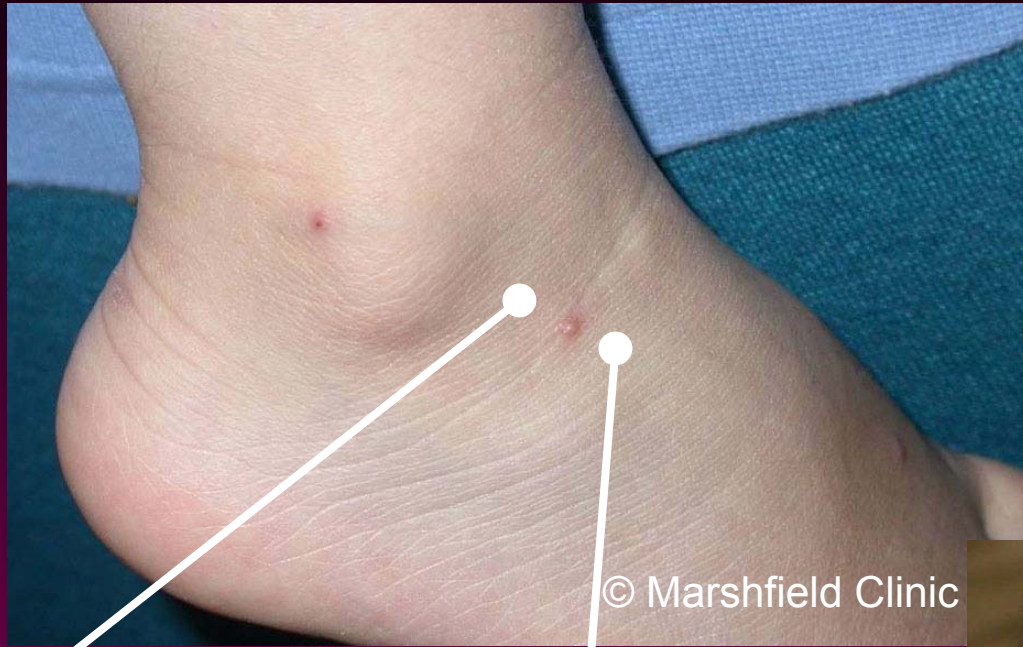


Child: Secondary lesions 5/27/03, adjacent to primary inoculation site on left hand.



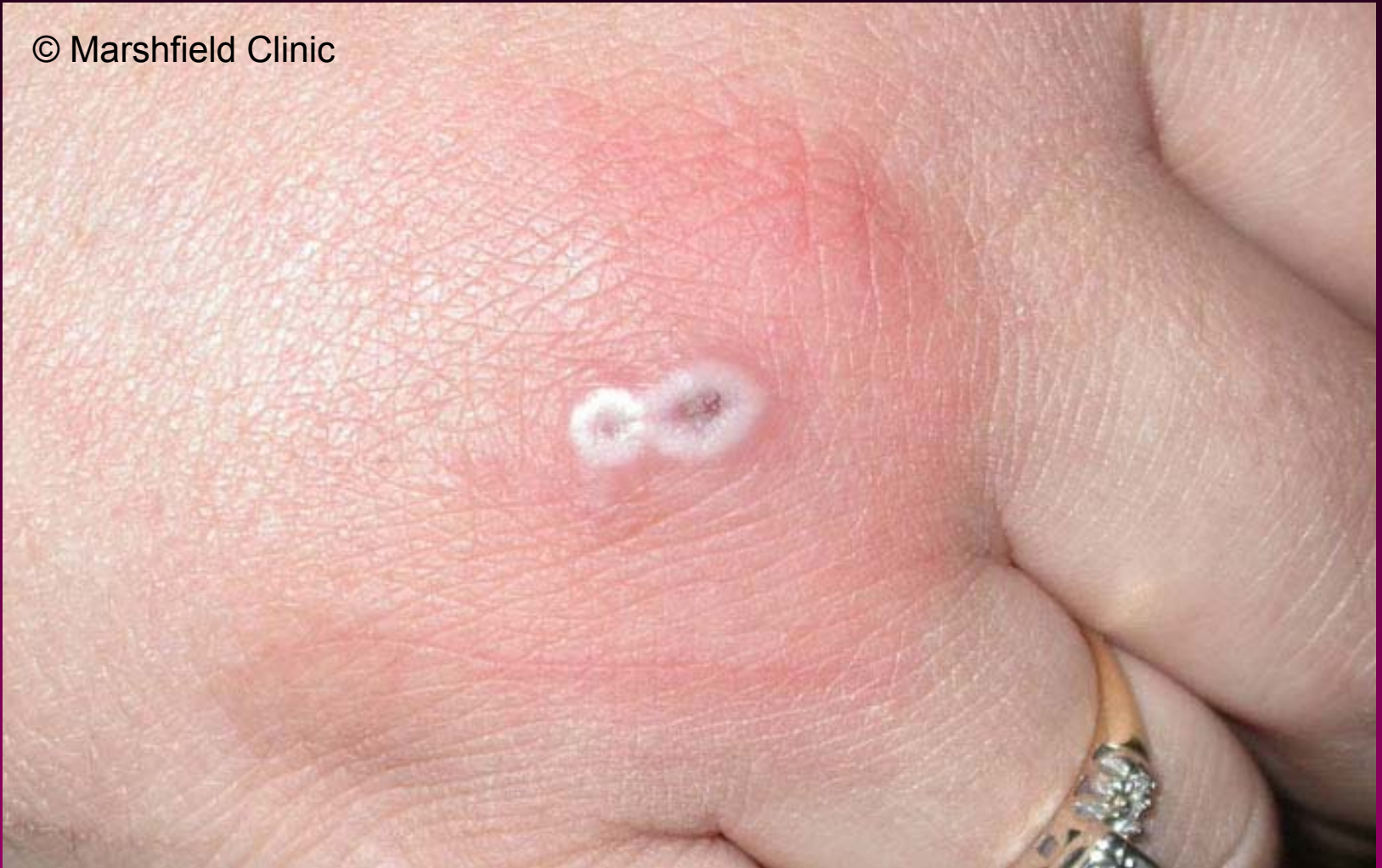

# Child: Disseminated acral lesions 5/27/03

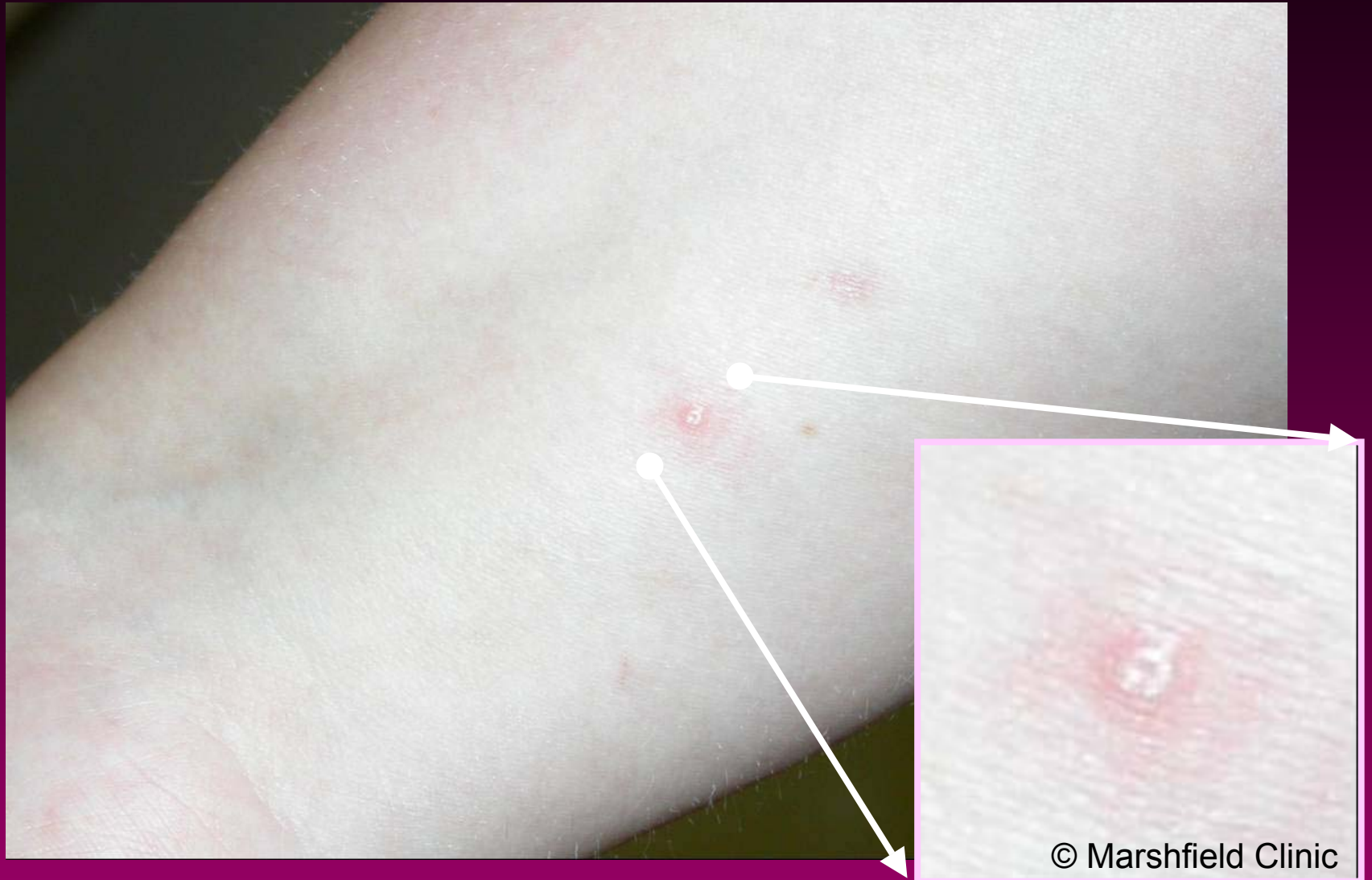

Mother, 5/27/03, 1 day after vesicles & erythema at site of cat scratch. Sweats, fever, and malaise the night of 5/26/03. Has sore throat.

© Marshfield Clinic

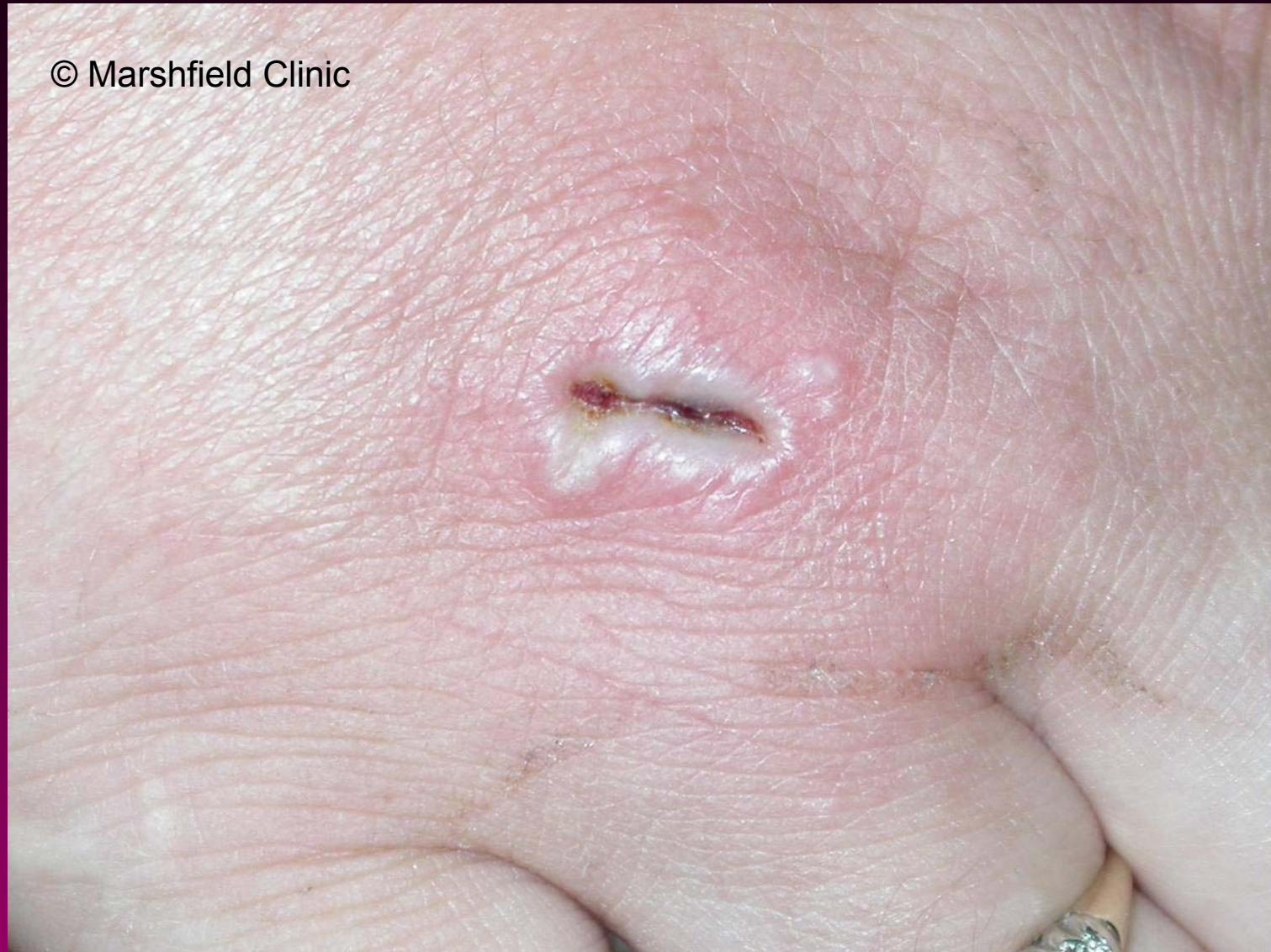

Mother: disseminated umbilicated vesicles 5/27/03.  
Sweats recur, less severe. Has sore throat.

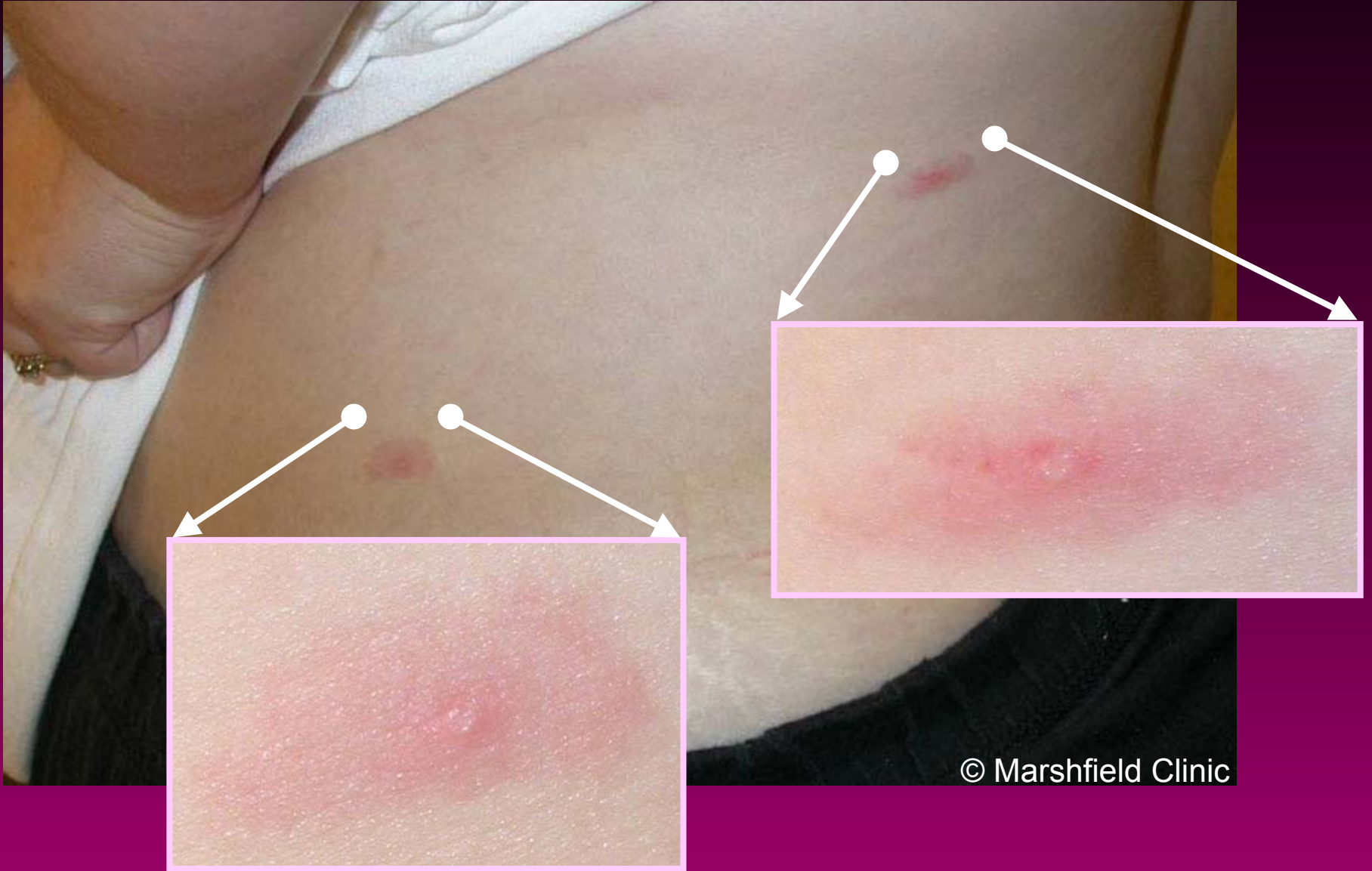



Mother, 5/29/03, expansion of vesicles beyond biopsy site of 5/27/03. Note satellite vesicles.

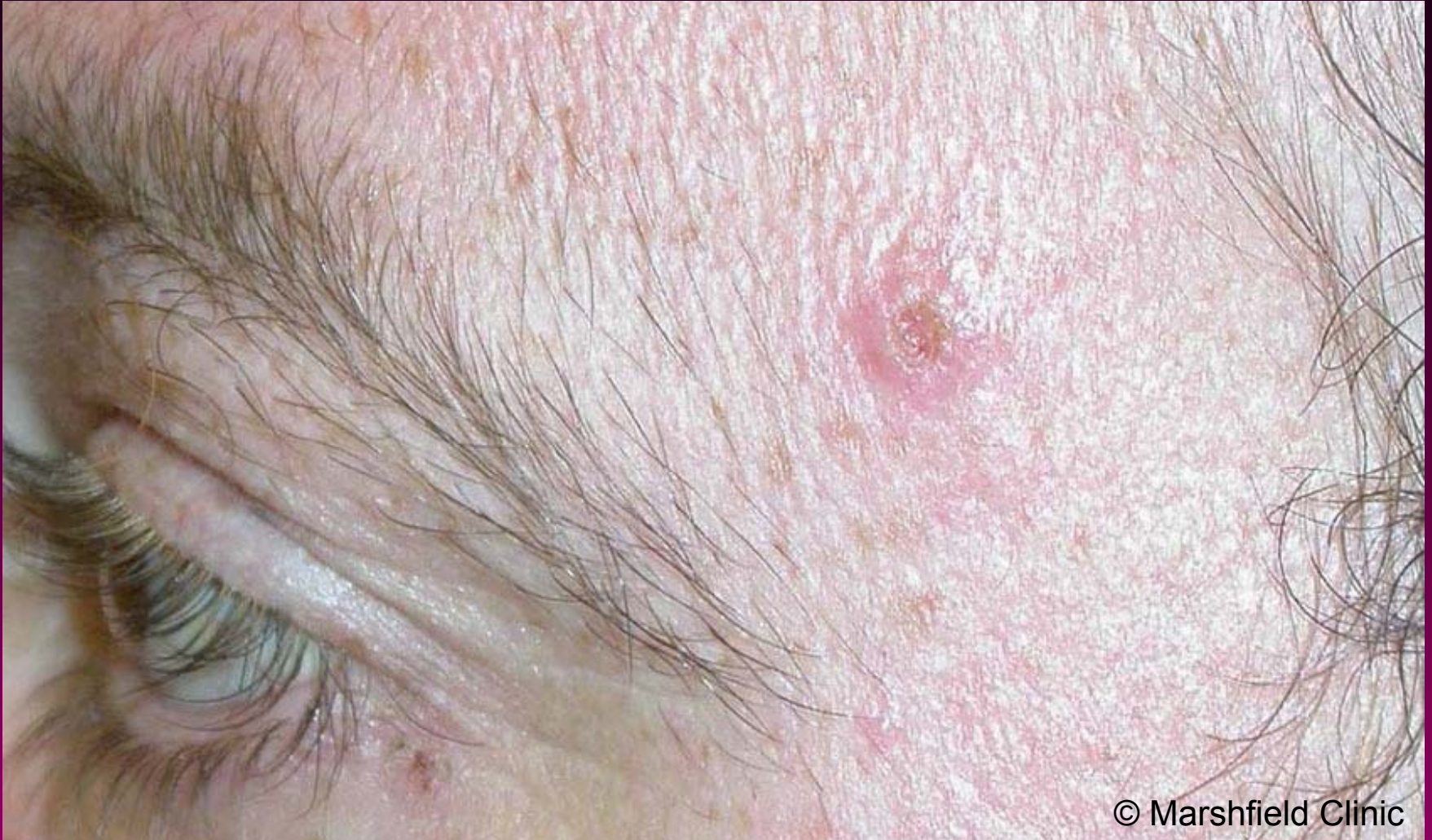

Mother, 5/29/03, umbilicated vesicles on red base.  
Feels well. Child discharged from hospital.



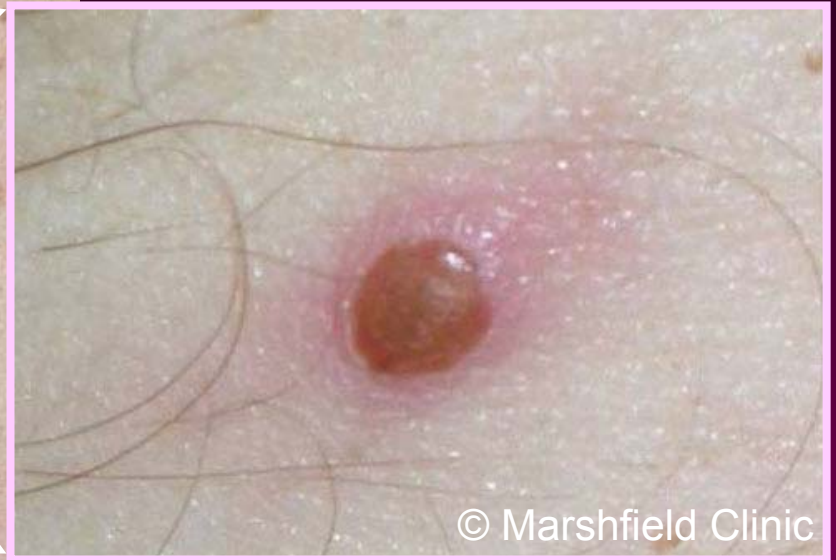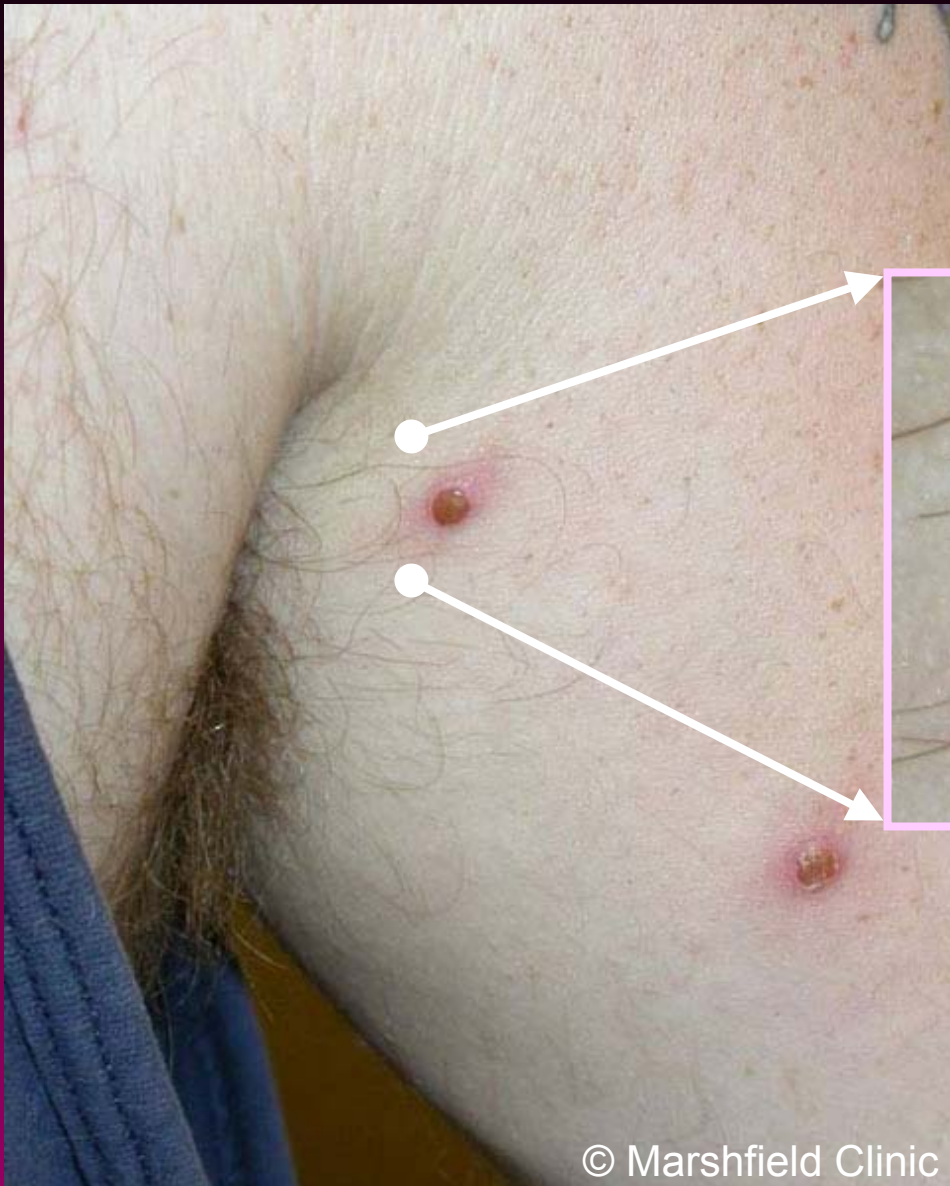


Father, 6/05/03, after fevers, sweats, malaise  
on 5/31-6/01/03. Feels well.



© Marshfield Clinic

# Father, 6/05/03

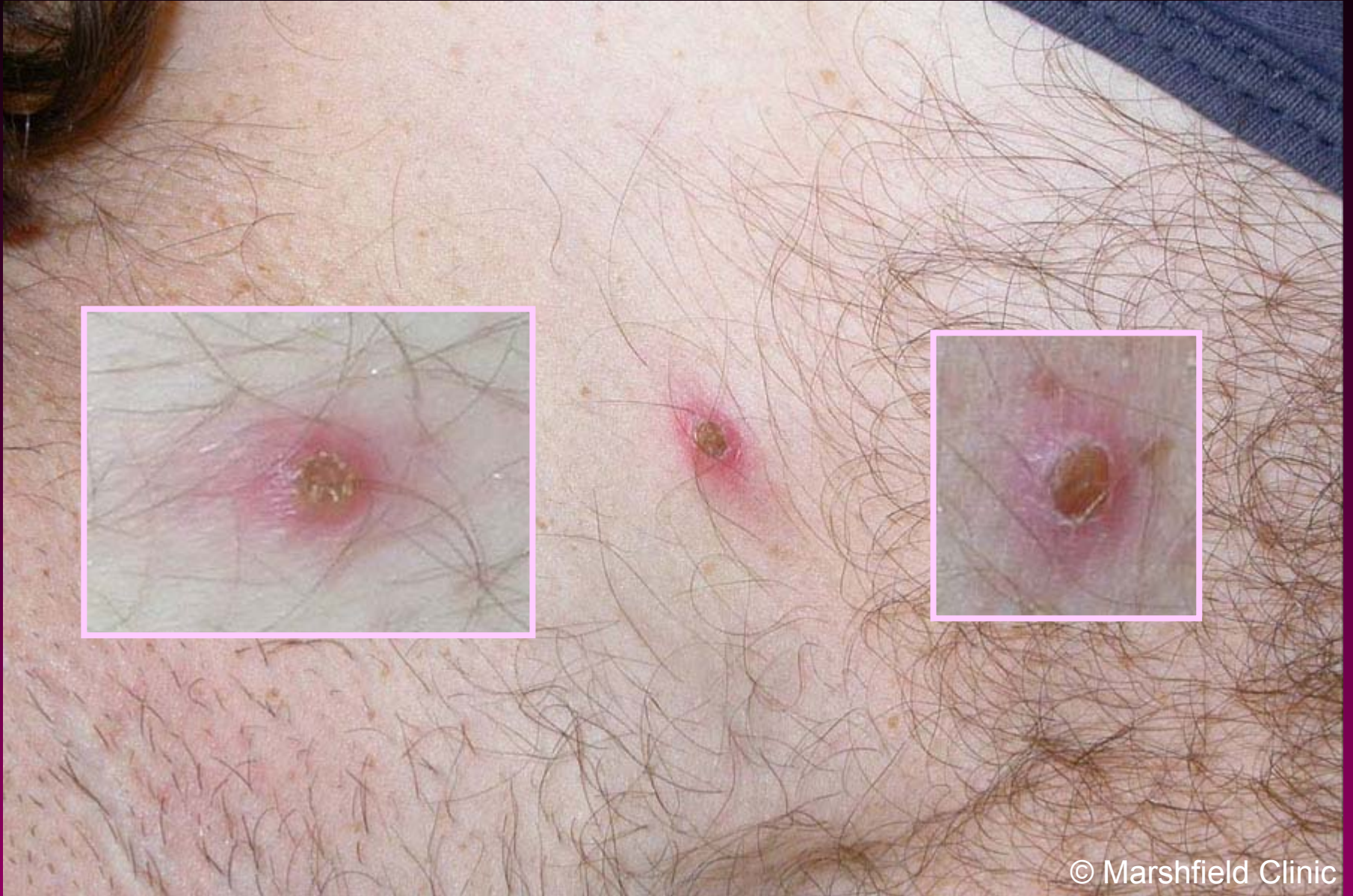

© Marshfield Clinic

© Marshfield Clinic

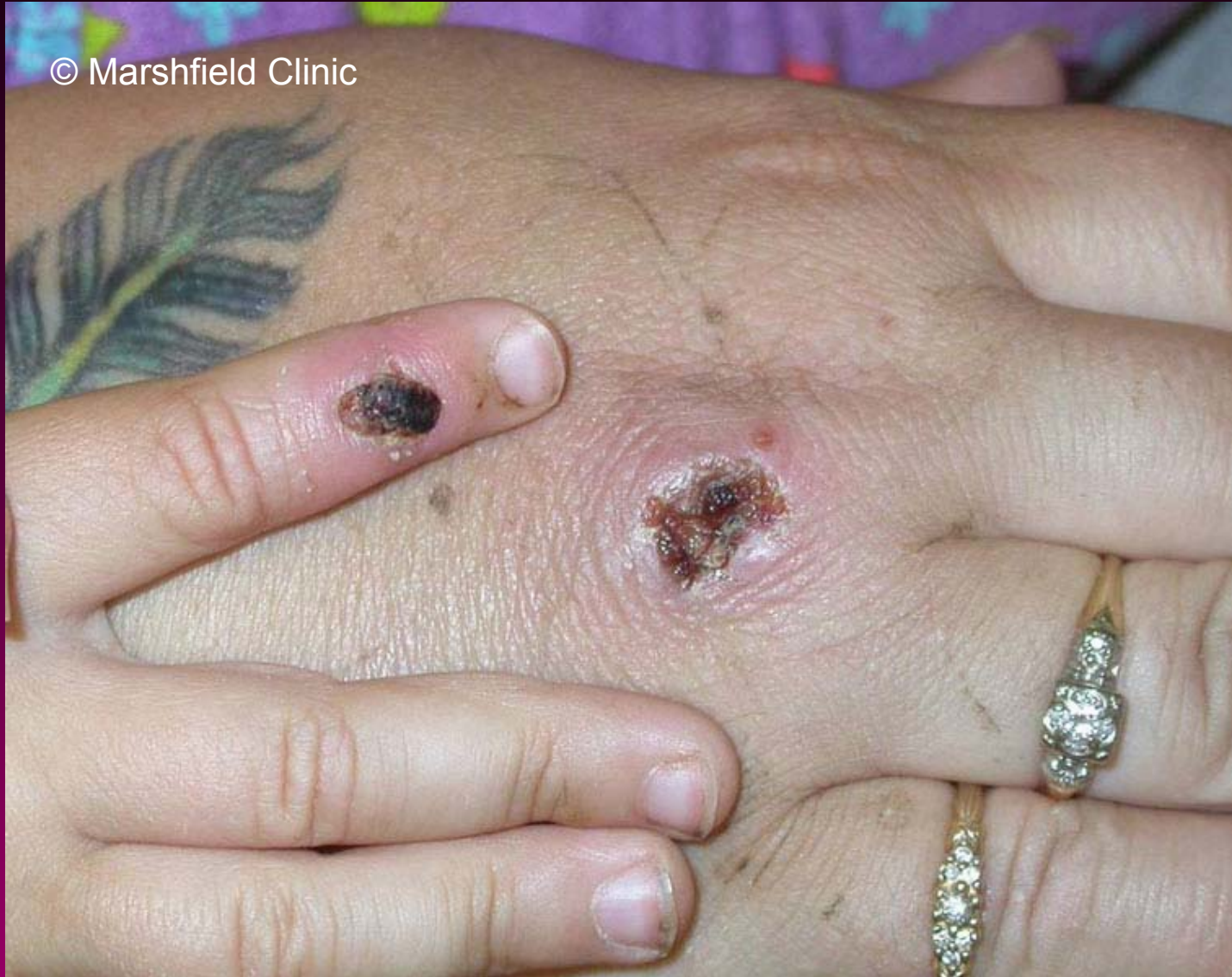

# Father, 6/05/03, trunk lesions



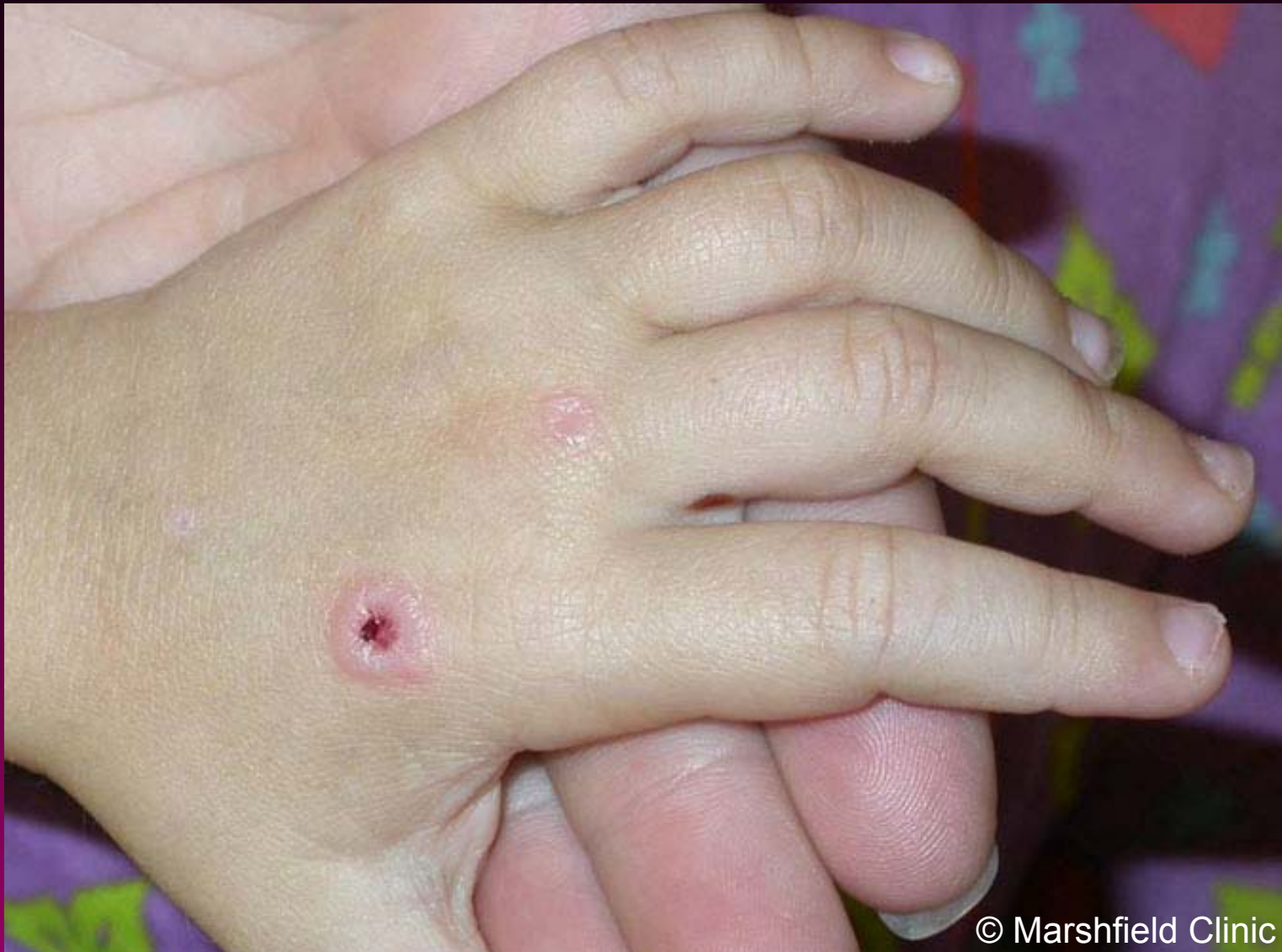Child and mother, 6/5/03, crusted primary inoculation sites. Both feeling well.

© Marshfield Clinic





Child, 6/5/03, resolving lesions.



© Marshfield Clinic

# Monkey pox story 2003 - Child

- 5/11, Mothers' Day, Two prairie dogs from pet swap meet in Wausau given to Mother in Dorchester, WI.
- 5/13 Prairie dog bites 3 1/2 year old daughter on right index finger and dorsal left hand.
- 5/15 Prairie dog seen by veterinarian due to skin lesions and discharge from nose and eyes. Prairie bites veterinarian technician.
- 5/16 Child get fevers, wounds are red.
- 5/20 Child seen by primary care physician. Lesions are raised and whitish and child has URI-like symptoms. Augmentin and Zithromax are started. Prairie dog dies. Head sent by veterinarian to Madison for rabies check, negative. Enlarged submandibular lymph gland harvested and sent to Marshfield Joint Venture Laboratory for cultures.



# Monkey pox story 2003 - Child

- 5/22 Child hospitalized because of festering wounds, fevers, sweats, right eye discharge, swelling around the right eye (from rubbing with wounded hands?), and new skin lesions, including scalp, perineum and extremities. Multiple IV antibiotics given including ciprofloxacin.
- 5/25 Dermatology consult obtained because of persistent fevers and new skin lesions. Primary inoculation sites on on right index finger and dorsal left hand have central hemorrhagic crusts with pustular borders. Disseminated papulovesicles and pustules have erythematous flares with central umbilication and/or hemorrhagic crusts. Lesions biopsied for aerobic culture and histology 12:30 AM. By 9 PM, histology report of extensive epidermal necrosis, cells with cytoplasmic inclusions and possible multinucleated cells. Stains for HSV I & II negative. Intravenous acyclovir started.

# Monkey pox story 2003 - Mother

- 5/27 28 year old mother gets vesiculation around cat scratch on dorsal right hand. Biopsies taken for viral culture, electron microscopy, and histology. Swab sent for aerobic culture. Mother has had drenching sweats, malaise, sore throat and does not feel well.
- 5/28 Mother has disseminated skin lesions. Has had more sweats, but feels better. Afebrile by oral temp.
- 5/29 Mother's primary lesion is re-biopsied. Disseminated lesion on right forearm biopsied. Mother feels better, but throat still sore, tonsils enlarged. Acute serum obtained. WBC 6.2 (23% bands, 39% segs, 24% lymph, 5% activated lymphs, 8% monos), CRP=5.3, chemistries normal. Throat culture negative Valacyclovir 1 gram tid. Mother kept out of work. Child discharged on ciprofloxacin.
- 5/30 Orthopox virus seen on mothers initial biopsy. Valacyclovir stopped. Orthopox virus cultured from skin.



# Monkey pox story 2003 - Father

- 5/31-6/1 38 year old father gets sweats, malaise and develops multiple skin lesions.
- 6/2 Primary care physician reports 12-15 disseminated skin lesions on all extremities, trunk and head. Father now feeling well but kept out of work.
- 6/5 Family seen in clinic. All feeling well. Primary lesions are crusted ulcerations. Mother's tonsils are smaller and she has no adenopathy. Father has at least two lesions that are still vesiculated and some axillary adenopathy. Acute serum and viral cultures obtain from father. Mother and Father told to stay out of work.
- 6/6 Family's 13 cats, 20 dogs, 7 horses, 4 goats, 3 donkeys and one recovering prairie dog are kept in quarantine.
- Orthopox virus cultured from prairie dog lymph node.